

# Traumatic Cervical Spinal Cord Injury: Correlation of Imaging Findings with Neurological Outcome

## *Lesão traumática da medula espinal cervical: Correlação de achados de imagem com laudo neurológico*

Shahrokh Yousefzadeh-Chabok<sup>1,2</sup> Khaterreh Asadi<sup>1,3</sup> Javid Jahanbakhsh<sup>4</sup> Enayatollah Homaie Rad<sup>5</sup>  
Zoheir Reihanian<sup>1,2</sup> Morteza Modaenama<sup>1</sup>

<sup>1</sup>Guilan Road Trauma Research Center, Guilan University of Medical Sciences, Rasht, Iran

<sup>2</sup>Neuroscience Research Center, School of Medicine, Guilan University of Medical Sciences, Rasht, Iran

<sup>3</sup>Department of Medical Nanotechnology, School of Advanced Medical Sciences and Technologies, Shiraz University of Medical Sciences, Shiraz, Iran

<sup>4</sup>Department of Radiology, School of Medicine, Guilan University of Medical Sciences, Rasht, Iran

<sup>5</sup>Social Determinants of Health Research Center, Guilan University of Medical Sciences, Rasht, Iran

**Address for correspondence** Khaterreh Asadi, PhD, Guilan Road Trauma Research Center, Guilan University of Medical Sciences, Rasht, Iran (e-mail: khaterreh70762@yahoo.com).

Arq Bras Neurocir

### Abstract

**Background** Traumatic spinal cord injury (TSCI) is extremely costly to the global health system. Due to the significant frequency rate of traumatic cervical spinal cord injuries (TCSCI), the possible association between imaging findings and clinical outcome is not yet clear. In this study, we quantified maximum spinal cord compression and maximum cord swelling following TCSCI and determined the relevance of imaging findings to clinical outcome in patients.

**Materials and Methods** This retrospective cohort comprises 20 patients with TCSCIs (C3-C7), classified as complete, incomplete, and no SCI, who were treated at the Poursina Hospital, Iran, from 2018 to 2020, and underwent spinal surgery. Patients with penetrating injuries and multiple trauma were excluded. Imaging findings revealing spinal cord compression, swelling, and canal stenosis, based on the American Spinal Injury Association (ASIA) Impairment Scale (AIS) grades of patients from hospital admission (up to 48 hours after injury) and improvement of postoperative neurological symptoms (6–12 months) were evaluated.

**Results** Cord compression ( $p = 0.05$ ) and cord swelling ( $p = 0.02$ ) were significantly related to predictive neurological outcomes in all cases. Evaluation with AIS at hospital admission and at 6 to 12 months postoperatively showed significant correlation with fracture type ( $p = 0.05$ ) and the longitudinal length of the intramedullary lesion (IML);  $p = 0.01$ , respectively.

### Keywords

- ▶ traumatic cervical spinal cord injury
- ▶ imaging findings
- ▶ neurological outcome

received  
February 6, 2021  
accepted  
December 20, 2021

DOI <https://doi.org/10.1055/s-0042-1748869>.  
ISSN 0103-5355.

© 2022. Sociedade Brasileira de Neurocirurgia. All rights reserved. This is an open access article published by Thieme under the terms of the Creative Commons Attribution-NonDerivative-NonCommercial-License, permitting copying and reproduction so long as the original work is given appropriate credit. Contents may not be used for commercial purposes, or adapted, remixed, transformed or built upon. (<https://creativecommons.org/licenses/by-nc-nd/4.0/>)  
Thieme Revinter Publicações Ltda., Rua do Matoso 170, Rio de Janeiro, RJ, CEP 20270-135, Brazil

## Resumo

### Palavras-chave

- ▶ lesão traumática da medula espinal cervical
- ▶ achados de imagem
- ▶ laudo neurológico

**Conclusion** According to the results obtained in this study, it may be concluded that there is a significant association between cervical spinal cord compression and swelling, and clinical outcomes in patients with complete, incomplete, and no SCI.

**Introdução** A lesão traumática da medula espinal (LTME) é extremamente onerosa para o sistema de saúde global. Devido à significativa taxa de frequência de lesões traumáticas da medula espinal cervical (TCSCI), a possível associação entre achados de imagem e evolução clínica ainda não está clara. Neste estudo, quantificamos a compressão medular máxima e o edema medular máximo após TCSCI e determinamos a relevância dos achados de imagem para o resultado clínico dos pacientes.

**Materiais e métodos** Esta coorte retrospectiva compreende 20 pacientes com TCSCIs (C3-C7), classificados como completos, incompletos e sem LME, que foram tratados no Hospital Poursina, Irã, de 2018 a 2020, e submetidos a cirurgia da coluna vertebral. Pacientes com lesões penetrantes e politraumatismos foram excluídos. Achados de imagem revelando compressão da medula espinhal, edema e estenose do canal, com base nos graus da American Spinal Injury Association (ASIA) Impairment Scale (AIS) de pacientes desde a admissão hospitalar (até 48 horas após a lesão) e melhora dos sintomas neurológicos pós-operatórios (6-12 meses) foram avaliados.

**Resultados** A compressão do cordão ( $p = 0,05$ ) e o edema do cordão ( $p = 0,02$ ) foram significativamente relacionados aos desfechos neurológicos preditivos em todos os casos. A avaliação com AIS na admissão hospitalar com 6 a 12 meses de pós-operatório mostrou correlação significativa com o tipo de fratura ( $p = 0,05$ ) e o comprimento longitudinal da lesão intramedular (IML);  $p = 0,01$ , respectivamente.

**Conclusão** De acordo com os resultados obtidos neste estudo, pode-se concluir que existe uma associação significativa entre compressão e edema da medula espinal cervical e desfechos clínicos em pacientes com lesão medular completa, incompleta e sem lesão medular.

## Introduction

Traumatic spinal cord injury (TSCI) is a catastrophic burden on the global health system;<sup>1</sup> it is classified as complete or incomplete injuries with a wide range of neurological outcomes that affect the functions associated with exact diagnostic and prognostic information.<sup>2</sup> In involved patients, the cervical region is responsible for 49% of spinal cord injuries (SCI) that result in real motor, sensory, and autonomic dysfunction below the level of injury.<sup>3</sup>

Handling of cervical spinal cord injury situations is performed by imaging and reliable physical, neurological, and electrophysiological examinations. The American Spinal Injury Association (ASIA) Impairment Scale (AIS) grades are the key neurological assessments to classify the severity of SCI patients. The AIS assessment results are highly sensitive for evaluation of expected short-, intermediate-, and long-term neurological outcomes. It also provides a better insight into the complete rehabilitation process for health care professionals.<sup>4,5</sup>

Plain radiography, computed tomography (CT) scan, and magnetic resonance imaging (MRI) are the imaging methods used to show spinal canal diameters and cord alteration in acute, sub-acute, and chronic SCI.<sup>4</sup> Midsagittal CT scan

images allow characterization of the fracture and lesion structure (hemorrhage and edema) at the focal spinal cord injury site as well as representation of canal diameter changes.<sup>6,7</sup> External compression on the spinal cord and internal structures by MRI is the best method. Midsagittal T2-weighted images can help mainly with spinal cord lesion quality and quantity evaluation to characterize injury structures.<sup>8-10</sup>

Several studies have been conducted to evaluate the relationship between MRI quantitative parameters and short-term neurologic outcomes. Preservations showed that maximum spinal cord compression (MSCC) could be the cornerstone in determining the severity of neurologic impairment such that initiating correct rehabilitation therapies and prevention of persistent injury is necessary and to predict the long-term outcome as accurately as possible.<sup>11-14</sup>

Even so, because of the large heterogeneity among SCI patients due to injury mechanisms, lesion patterns, cervical degenerative diseases, type of spine fractures, and therapeutic approach, prediction of the possible association between clinical and imaging findings as sufficiently accurate markers of long-term neurologic outcomes has not been established. Additionally, clinical studies for traumatic cervical spinal cord injuries (TCSCI) and follow-up are fraught with several

complicating factors. They comprise imaging procedures that accurately neurologically examine patients. In this study, we intend to associate imaging quality with fracture type, maximum osseous canal compromise (MCC), spinal cord compression, swelling, and intramedullary lesion (IML) length, with the aim of predicting postoperative neurological improvement in traumatic cervical spinal cord injury patients with follow-up at 6 to 12 months.

## Materials and Methods

In this retrospective cohort study, 20 patients with TCSCI treated at the Poursina Hospital, Iran, from 2018 to 2020, based on the National Spinal Cord Injury Registry of Iran (NSCIR-IR) database were assessed. The study was approved by the local ethical committee and the ethical code (IR.GUMS.REC.1398.529) was received.

The imaging was done for all cases with a single device. For CT scans, the HITACHI 16-slice (Hitachi Ltd., Chiyoda, Japan) scanner was used, and for MRI the Philips 1 Tesla (Koninklijke Philips N.V., Amsterdam, Netherlands) was used.

Imaging evaluation was performed twice by two neurosurgeon observers at different time points at a picture archiving and communication system (PACS) station. At the time of the assessments, the observers were blinded for clinical and neurological data.

We extracted patients' essential demographic features and clinical information from their electronic medical records; the collected data was organized in ►Table 1.

### Inclusion and Exclusion Criteria

The inclusion criteria were patients aged from 15 to 70 years. Only those with preoperative MRI and CT scans were enrolled. All cases were operated up to 48 hours after trauma.

**Table 1** Imaging parameters and evaluation

| Imaging parameters                  | Evaluation  |
|-------------------------------------|---|
| Type of fracture                    | A0 classification system  |
| MCC (%)                             | $(1-d_i/d_m)*100$ if $d_m = (d_a + d_b)/2$                                    |
| MSCC (%)                            | $(1-d_i/d_m)*100$ if $d_m = (d_a + d_b)/2$                                    |
| MCS (%)                             | $(d_s/d_m-1)*100$ if $d_m = (d_a + d_b)/2$                                    |
| Longitudinal length of the IML (mm) | Length of the hyperintense signal in the spinal cord on T2 weighted MRI views |

**Abbreviations:** IML, intramedullary lesion; MCC, maximum osseous canal compromise; MCS, maximum cord swelling; MSCC, maximum spinal cord compression.

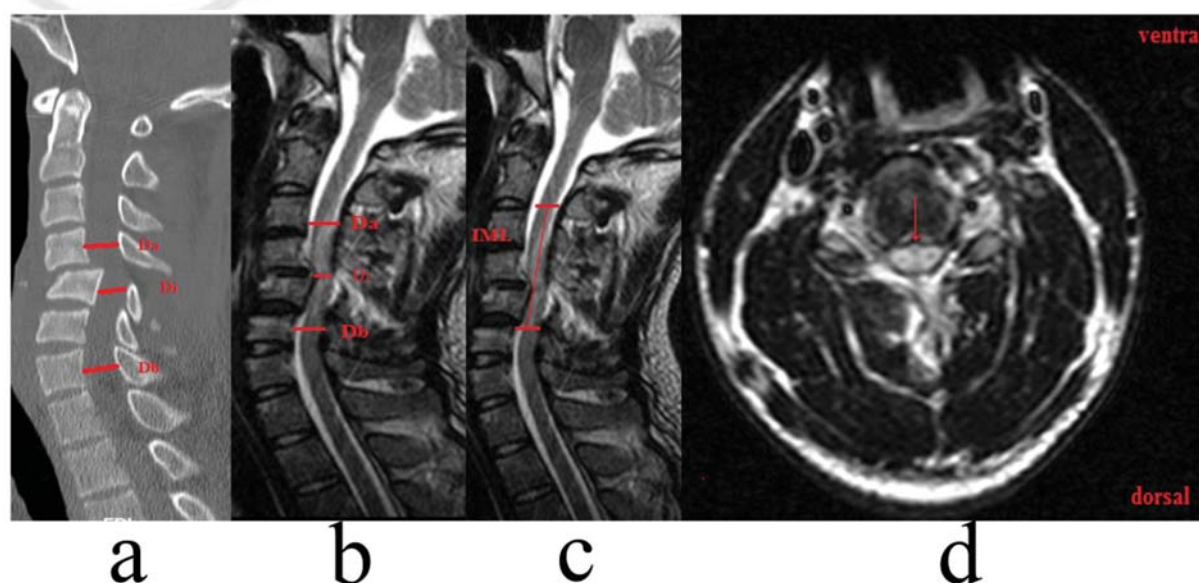
The exclusion criteria were penetrating thoracolumbar spinal cord injury, multiple trauma, severe head trauma (Glasgow coma score < 13), spinal shock after trauma, severe chest weakness, hemodynamic instability due to hemorrhage of abdomen/retroperitoneal space, pelvic fracture, presence of fracture in more than three long bones, complete spinal injury, chronic severe degenerative lesions identified through CT scan and MRI, and low-quality imaging with inaccurate measurements.

### Imaging Parameters

The type of fractures was determined based on the AOSpine Trauma Classification system.<sup>15</sup>

The MCC was measured based on CT scan mid-sagittal images. The other variables were evaluated following T2-weighted mid-sagittal images; they can be defined, briefly, as:

- MCC is determined by splitting the anteroposterior canal diameter at the affected zone ( $D_i$ ) by the average



**Fig. 1** (a) midsagittal CT scan, (b) and (c) midsagittal T2-weighted, (d) axial T2-weighted obtained from 24 years old man with acute TCSCI at C4-C5 level (AIS grade C). (Da) anteroposterior spinal cord diameter at 1 vertebral level above; (Db) anteroposterior spinal cord diameter at 1 vertebral level below; (Di) anteroposterior spinal cord diameter at injury site; IML: rostrocaudal length of intramedullary hyperintensity at the injury site. Arrow in axial T2-weighted displayed intramedullary hyperintensity and cord compression in the affected zone.

**Table 2** Patients characteristics

|                                    |                   |          |
|------------------------------------|-------------------|----------|
| Number of patients                 | 20                |          |
| Gender, female/male                | 0/20              |          |
| Age (mean, SD, year)               | 44.7 ± 15.4 years |          |
| <b>Occupation</b>                  | <b>(n)</b>        | <b>%</b> |
| Reconstruction workers             | 5                 | 25       |
| Farmer                             | 4                 | 20       |
| Employee                           | 4                 | 20       |
| Shopkeeper                         | 2                 | 10       |
| Engineer                           | 2                 | 10       |
| Others                             | 3                 | 15       |
| <b>Trauma mechanism</b>            |                   |          |
| Fall                               | 12                | 60       |
| Accident                           | 8                 | 40       |
| Others                             | 0                 |          |
| <b>Smoking/alcohol consumption</b> | 4/7               |          |
| <b>Background diseases</b>         |                   |          |
| None                               | 10                | 50       |
| Coronary artery disease            | 3                 | 15       |
| Hepatic disease                    | 1                 | 5        |
| Covid-19                           | 4                 | 20       |
| Renal disease                      | 2                 | 10       |
| <b>Injury level</b>                |                   |          |
| C3                                 | 2                 | 10       |
| C4                                 | 6                 | 30       |
| C5                                 | 8                 | 40       |
| C6                                 | 2                 | 10       |
| C7                                 | 2                 | 10       |
| <b>Fracture classification</b>     |                   |          |
| A0                                 | 3                 | 15       |
| A1                                 | 1                 | 5        |
| A2                                 | 1                 | 5        |
| A3                                 | 7                 | 35       |
| A4                                 | 2                 | 10       |
| C                                  | 5                 | 25       |
| <b>Treatment (no [%])</b>          |                   |          |
| Surgical anterior approach         | 20                | 100      |

of the normal canal diameter size within 1 vertebral level above (Da) and below (Db).

- MSCC is determined by splitting the anteroposterior canal diameter at the affected zone (Di) by the average of the normal canal diameter size within 1 vertebral level above (Da) and below (Db).
- Maximum cord swelling (MCS) is determined by the maximum swollen (Ds) anteroposterior spinal cord diameter at the affected zone and within 1 vertebral level above (Da) or below (Db).

**Table 3** Patients' AIS grade at hospital admission and at 6 to 12 months follow-up

| AIS grade                                | AIS-A | AIS-B | AIS-C | AIS-D | AIS-E | p-value |
|--|-------|-------|-------|-------|-------|---------|
| AIS grade at admission (no [%])          | 1     | 5     | 4     | 7     | 3     | 0.01    |
| AIS grade follow-up 6–12 months (no [%]) | 1     | 2     | 3     | 6     | 9     |         |

Abbreviations: AIS, American spinal injury association impairment scale.

- Longitudinal length of IML, which is the rostrocaudal length of intramedullary changes. (► **Figure 1**)

### Neurological Assessment

Clinical examinations for neurological symptoms were done according to the AIS score system. Baseline AIS grading was done up to 48 hours after patients' admission at the hospital, presurgery. Long-term follow-up (6–12 months) of neurological evaluations postsurgery were performed by neurosurgeons through scheduled visits at the hospital clinic.

### Statistical Analysis

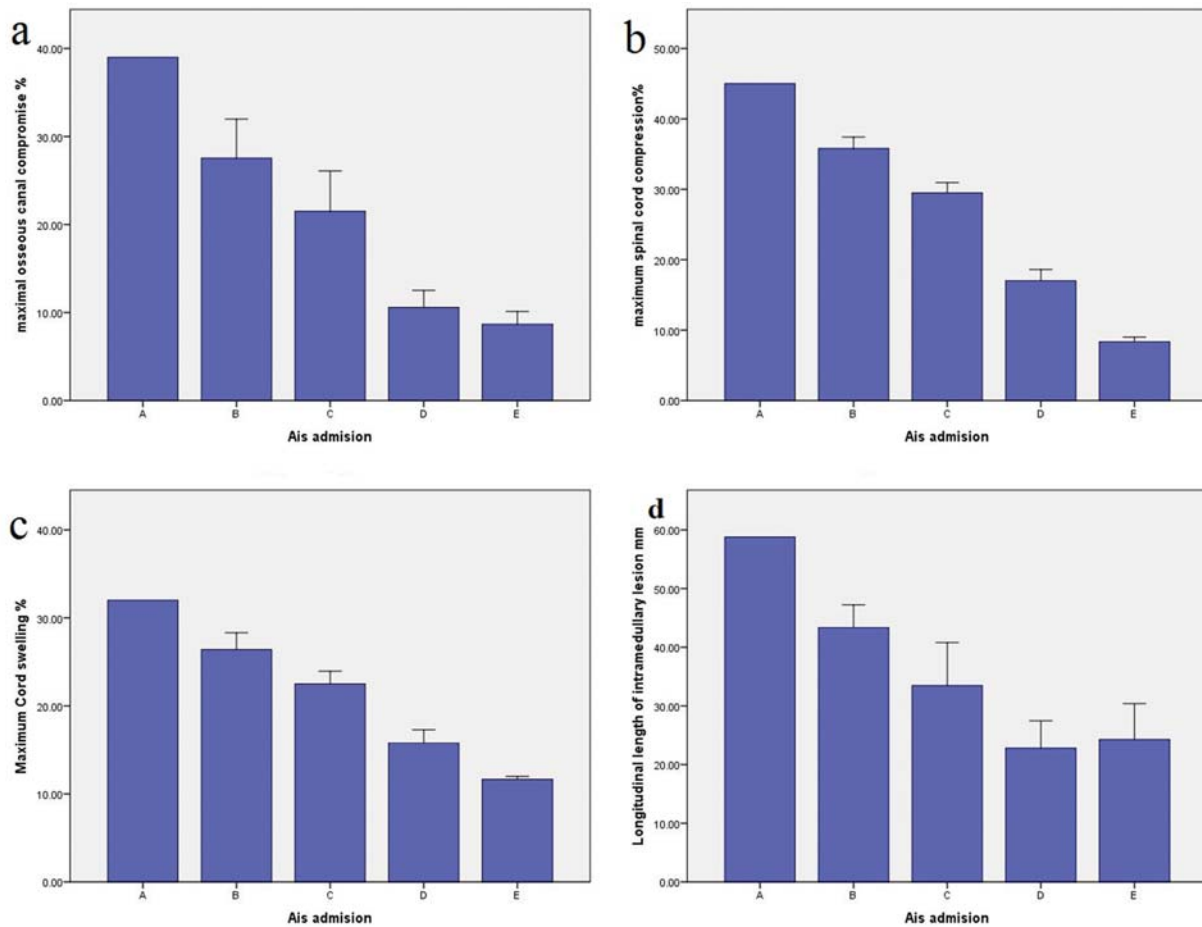
Data analysis was done with the Statistical Package Social Sciences (SPSS, IBM Corp. Armonk, NY, USA) software, version 21.0. The utilized tests were the Kolmogorov-Smirnov test, paired sample T-test, Pearson correlation coefficient, Spearman test, and independent sample T-test. All p-values lower than 0.05 were considered statistically significant.

### Results

All 20 cases were male subjects, and the mean age was  $45.5 \pm 15.1$  years. The treatment performed in all patients was an anterior surgical approach. Falling (60%) and vehicle accidents (40%) were the main causes of trauma in these patients. None of these patients underwent steroid therapy. As might be expected, more than half of the patients included had an incomplete injury with AIS grades C and D, and the most numerous neurological levels of injury (NLI) were C4–C5. The list of comorbidities evaluated in this study is present in ► **Table 2**. Incomplete burst fractures (35%) and type C fractures (translocation) (25%) were the most common among patients.

The initial and follow-up AIS scores are shown in ► **Table 3**; there was a significant difference between them ( $p = 0.01$ ).

Mean MCC on the initial MRI ranged from 39 to 9% for AIS scores A to E (► **Fig. 2a**). Mean MSCC on the initial MRI ranged from 45 to 7% for AIS scores A to E (► **Fig. 2b**). Mean MSC on the initial MRI ranged from 32 to 13% for AIS scores A to E (► **Fig. 2c**). Mean IML on the initial MRI ranged from 58 to 23 mm for AIS scores A to E (► **Fig. 2d**).<sup>16</sup>



**Fig. 2** (a) Mean MCC on the initial MRI for each AIS grade; (b) MSCC on the initial MRI for each AIS grade; (c) MCS in the initial MRI for each AIS grade; (d) longitudinal length of the IML for each AIS grade. Error bars indicate standard deviation (SD).

**Table 4** Correlation of AIS with imaging findings

| Parameters                          | AIS at admission | p-value | AIS at follow-up | p-value |
|-------------------------------------|------------------|---------|------------------|---------|
| CT maximum osseous canal compromise | 0.790            | 0.001   | 0.713            | 0.001   |
| MSCC                                | 0.925            | 0.001   | 0.870            | 0.001   |
| MCS                                 | 0.880            | 0.001   | 0.793            | 0.001   |
| Longitudinal length of IML          | 0.666            | 0.01    | 0.629            | 0.03    |
| Fracture type                       | 0.606            | 0.05    | 0.615            | 0.05    |

**Abbreviations:** AIS, American spinal injury association impairment scale; CT, computed tomography; IML, intramedullary lesion; MCC, maximum canal compromise; MCS, maximum cord swelling; MSCC, maximum spinal cord compression.

In this study, the correlation between AIS at admission and follow-up with imaging parameters were assessed and the results are present in **Table 4**. Imaging findings had a significant correlation with patients' neurological outcome, which was evaluated based on the AIS test.

According to the data present in **Table 5**, the MCC ( $p=0.74$ ) and longitudinal length of IML ( $p=0.24$ ) were not significantly related to the improvement in patients. Conversely, maximum spinal cord compression ( $p=0.05$ ), and maximum cord swelling ( $p=0.02$ ) had a significant association with patient improvement.

## Discussion

In this study, we assessed the relationship between imaging quantitative features with improvement of postoperative neurological symptoms (according to AIS) in patients with TCSCI without prior neurodegenerative diseases. This study's findings demonstrate that the presence of greater cord compression and swelling is a prognostic factor to predict the long-term neurological outcomes in patients under surgery.

Considering that most of the cervical spinal cord injuries are incomplete, the cause/mechanism of the SCI and

**Table 5** The association of patient improvement with imaging findings

| Quantitative parameters         | Improvement ( <i>p</i> -value) |
|---------------------------------|--------------------------------|
| CT MCC                          | 0.74                           |
| Maximum spinal cord compression | 0.05                           |
| Maximum cord swelling           | 0.02                           |
| Longitudinal length of IML      | 0.24                           |

Abbreviations: CT, computed tomography; IML, intramedullary lesion; MCC, maximum osseous canal compromise; MCS, maximum cord swelling; MSCC, maximum spinal cord compression.

rehabilitation outcomes should not be conflated. In a study by Kiwerski, it was reported that the cause of the injury impacts the level of the spinal cord lesion. Moreover, the incidence of injuries from a flexion mechanism is more prevalent.<sup>17</sup> According to some studies, the highest leading cause of SCI in younger patients followed by motor vehicle accidents, sports, trauma, suicide attempts, and acts of violence was occurring. Falling was significantly the cause of TSCI in older patients (62.3%)<sup>18</sup>. In this study, TSCI was associated with cervical spinal cord lesion, caused by falls in 60% of cases, of whom 26% were construction workers, and 13% were farmers. However, patients with significant MSCC and MCS, as well as severe functional impairment, were more prevalent in motor vehicle accidents.

In this study, we found that falling was the main cause of TSCI in patients, which could be related to the work opportunities in the north of Iran, predominantly farming and reconstruction. Another study<sup>19</sup>, which evaluated age, gender, BMI, and administration of steroids, determined that these items did not correlate with neurological outcomes and AIS follow-up. In our study, we found that the prevalence of TSCI is more common in male patients; however, the effect of administration of steroids was not evaluated in this study because the protocol prescribes the same treatment for all patients based on internal guidelines.

The first clinical evidence was presented by Firoz Miyajani et al.<sup>9</sup> who reported a significant correlation between AIS follow-up was 7.3 months (range, 1–35 months) evaluation with intramedullary hemorrhage and cord swelling at the time of injury. Furthermore, they suggested that the extent of MSCC is more reliable than the presence of canal stenosis for predicting the neurological outcomes after SCI. In our study, as shown in ► **Fig. 2**, we demonstrated that MSCC and MCS had a great relation with neurological outcomes. Patients with AIS grades A and B had MSCC and MCS over 38 and 28%, respectively. Additionally, in the present study, we evaluated the correlation of fracture type and the longitudinal length of IML with neurological outcomes in all patients. Patients with AIS grades A, B, and C usually had worsened fracture type and extensive IML. However, patients with AIS grades D and E mostly had milder fracture types and mild IML lesions. Sometimes, transitional fractures could be seen in patients with AIS grades D and E. It should be mentioned that transitional fractures could be treated by surgical approach. Low-grade

transitional fractures in patients without significant degenerative SCIs could not lead to the neurological deficit in patients.

Another study by Rutges et al.<sup>20</sup> demonstrated an increase in vertical length of spinal cord edema in the first 48 hours after SCI, followed by a gradual decrease in the 3 weeks after injury. The MCC and MSCC reported in these studies range from 22 to 62% and 23 to 58%, respectively, for complete injuries, and from 14 to 38% and 20 to 52%, respectively, for incomplete injuries.<sup>9,13,16</sup> All cases included in this study required emergency surgical treatment; therefore, follow-up regarding cord swelling was not possible for these patients. However, the qualitative assessment of T2 images from patients after 6 months showed no sign of cord swelling.

A Canadian study by Oichi T et al.<sup>21</sup> demonstrated that preexisting severe cervical cord compression is an independent risk factor for severe paralysis once patients develop traumatic CSCI without bone injury. Preexisting severe cervical cord compression could interfere with patients' AIS score and imaging quantitative evaluations. In the current study, we investigated imaging parameters on patients without preexisting severe cervical cord compression with bone injury. The obtained results confirmed the relationship of traumatic spinal cord compression with neurological deficits.

Finally, H. Francis Farhadi<sup>22</sup> assessed the sensitivity and specificity of MRI parameters by including MCC, maximum spinal cord compression (MSCC), the longitudinal length of the IML, with the Brain and Spinal Injury Center (BASIC) score, and a novel derived Combined Axial and Sagittal Score (CASS). Both BASIC and IML were stronger predictors of AIS conversion when compared with MCC and MSCC ( $p = 0.0002$  and  $p = 0.04$ ). In the present study, as shown in ► **Table 4**, we found that IML was correlated with AIS at admission and follow-up 6 to 12 months postoperatively. However, we showed, in ► **Table 5**, that the patients' improvement had no significant relationship with those factors. Additionally, AIS-C and -D patients had the best neurologic improvement. We suggest that other studies are required to corroborate these results. Another limitation of our study is the small sample size per AIS grade, especially the AIS-A group ( $n = 1$ ).

## Conclusion

According to the obtained results, it may be concluded that there is a significant association between clinical and functional outcomes with spinal cord compression and cord swelling in TSCI patients. Hence, these are applicable variables to predict the final outcomes in patients with mild to acute cervical spinal cord injury. However, studies with a larger sample population and longer follow-up times are required to attain more reliable results.

### Conflict of Interests

The authors have no conflict of interests to declare.

## References

- 1 Furlan JC, Sakakibara BM, Miller WC, Krassioukov AV. Global incidence and prevalence of traumatic spinal cord injury. *Can J Neurol Sci* 2013;40(04):456–464

- 2 Harkey HL III, White EA IV, Tibbs RE Jr, Haines DE. A clinician's view of spinal cord injury. *Anat Rec B New Anat* 2003;271(01):41-48
- 3 Ihalainen T, Rinta-Kiikka I, Luoto TM, Koskinen EA, Korpijaakko-Huuhka AM, Ronkainen A. Traumatic cervical spinal cord injury: a prospective clinical study of laryngeal penetration and aspiration. *Spinal Cord* 2017;55(11):979-984
- 4 Krishna V, Andrews H, Varma A, Mintzer J, Kindy MS, Guest J. Spinal cord injury: how can we improve the classification and quantification of its severity and prognosis? *J Neurotrauma* 2014;31(03):215-227
- 5 van Middendorp JJ, Goss B, Urquhart S, Atresh S, Williams RP, Schuetz M. Diagnosis and prognosis of traumatic spinal cord injury. *Global Spine J* 2011;1(01):1-8
- 6 Song K-J, Choi B-W, Kim S-J, Kim G-H, Kim Y-S, Song J-H. The relationship between spinal stenosis and neurological outcome in traumatic cervical spine injury: an analysis using Pavlov's ratio, spinal cord area, and spinal canal area. *Clin Orthop Surg* 2009;1(01):11-18
- 7 Iclal ET, Lomasney LM, Jones NS, et al. A practical radiographic visual estimation technique for the prediction of developmental narrowing of cervical spinal canal. *Br J Radiol* 2017;90(1078):20170286
- 8 Skeers P, Battistuzzo CR, Clark JM, Bernard S, Freeman BJC, Batchelor PE. Acute thoracolumbar spinal cord injury: relationship of cord compression to neurological outcome. *J Bone Joint Surg Am* 2018;100(04):305-315
- 9 Miyajima F, Furlan JC, Aarabi B, Arnold PM, Fehlings MG. Acute cervical traumatic spinal cord injury: MR imaging findings correlated with neurologic outcome—prospective study with 100 consecutive patients. *Radiology* 2007;243(03):820-827
- 10 Fehlings MG, Martin AR, Tetreault LA, et al. A Clinical Practice Guideline for the Management of Patients With Acute Spinal Cord Injury: Recommendations on the Role of Baseline Magnetic Resonance Imaging in Clinical Decision Making and Outcome Prediction. *Global Spine J* 2017;7(3, Suppl):221S-230S
- 11 Song K-J, Ko JH, Choi B-W. Relationship between magnetic resonance imaging findings and spinal cord injury in extension injury of the cervical spine. *Eur J Orthop Surg Traumatol* 2016;26(03):263-269
- 12 Seif M, Gandini Wheeler-Kingshott CAM, Cohen-Adad J, Flanders AE, Freund P. Guidelines for the conduct of clinical trials in spinal cord injury: Neuroimaging biomarkers. *Spinal Cord* 2019;57(09):717-728
- 13 Ronzi Y, Perrouin-Verbe B, Hamel O, Gross R. Spinal cord injury associated with cervical spinal canal stenosis: Outcomes and prognostic factors. *Ann Phys Rehabil Med* 2018;61(01):27-32
- 14 Naik BR, Sakalecha AK, Savagave SG. Evaluation of traumatic spine by magnetic resonance imaging and its correlation with clinico-neurological outcome. *J Emerg Trauma Shock* 2019;12(02):101-107
- 15 Divi SN, Schroeder GD, Oner FC, et al. AOSpine-Spine Trauma Classification System: The Value of Modifiers: A Narrative Review With Commentary on Evolving Descriptive Principles. *Global Spine J* 2019;9(1, Suppl)77S-88S
- 16 Ulbrich EJ, Schraner C, Boesch C, et al. Normative MR cervical spinal canal dimensions. *Radiology* 2014;271(01):172-182
- 17 Kiwerski J. The influence of the mechanism of cervical spine injury on the degree of the spinal cord lesion. *Paraplegia* 1991;29(08):531-536
- 18 Liu J, Liu HW, Gao F, Li J, Li JJ. Epidemiological features of traumatic spinal cord injury in Beijing, China. *J Spinal Cord Med*. Doi: 10.1080/10790268.2020.1793505
- 19 Banaszek D, Inglis T, Marion TE, Charest-Morin R, Moskven E, Rivers CS, Kurban D, Flexman AM, Ailon T, Dea N, Kwon BK. Effect of frailty on outcome after traumatic spinal cord injury. *Journal of neurotrauma* 2020 Mar 15 2018;37(06):839-845
- 20 Rutges JPHJ, Kwon BK, Heran M, Ailon T, Street JT, Dvorak MF. A prospective serial MRI study following acute traumatic cervical spinal cord injury. *Eur Spine J* 2017;26(09):2324-2332
- 21 Oichi T, Oshima Y, Okazaki R, Azuma S. Preexisting severe cervical spinal cord compression is a significant risk factor for severe paralysis development in patients with traumatic cervical spinal cord injury without bone injury: a retrospective cohort study. *Eur Spine J* 2016;25(01):96-102
- 22 Farhadi HF, Kukreja S, Minnema A, et al. Impact of Admission Imaging Findings on Neurological Outcomes in Acute Cervical Traumatic Spinal Cord Injury. 2018;35(12):1398-1406